


To develop human resource potential and achieve a higher quality of life and a longer age, nutritional factors, diet and home remedies to overcome Angular cheilitis for children play a very important role. Because it is appropriate for nutrition, diet and home remedies for children to concern us all This book explains the understanding and problems of angular cheilitis in children, predisposing factors of angular cheilitis, nutritional deficiencies implicated in angular cheilitis, nutrition management of angular cheilitis in childrens




I Gusti Ayu Ari Agung
Dewa Made Wedagama
I Gusti Ayu Mahatma Agung (Ed.)



To develop human resource potential and achieve a higher quality of life and a longer age, nutritional factors, diet and home remedies to overcome Angular cheilitis for children play a very important role. Because it is appropriate for nutrition, diet and home remedies for children to concern us all

Angular cheilitis : Malnutrition, Diet and Home Remedies in children



978-620-0-11825-7

 **LAMBERT**
Academic Publishing

Authors

I Gusti Ayu Ari Agung
Dewa Made Wedagama

Editors

I Gusti Ayu Mahatma Agung

Angular cheilitis : **Malnutrisi, Diet and** **Home Remedies in Children**

Departement of Dental and Oral Health Sciences,
Faculty of Dentistry, Mahasaraswati Denpasar University.
Email : ayuariagung@gmail.com

Foreword

Thankfully we pray before the Almighty God, for his gift, the author can complete the publication of the book entitled “*Angular cheilitis: Malnutrition, Diet and Home Remedies in Children*”.

This book aims to study academically the notions and functions of nutrition, angular cheilitis and its problems, as well as efforts to overcome them. Thank you and high appreciation from the author to various parties for their attention and assistance.

Hopefully this book can be useful for the wider community. Constructive criticism and suggestions, for the sake of the perfection of this book we always wait happily, and we thank you very much.

Denpasar, June 2019
Author

CONTENTS

Part I Introduction.....	1
Part II Clinical Overview of <i>Angular cheilitis</i>	5
Part III Predisposing Factors of <i>Angular cheilitis</i>	9
Part IV <i>Angular cheilitis</i> Induced by Vitamin B and Folic Acid Deficiency.....	15
Part V <i>Angular cheilitis</i> Induced by Vitamin Iron and Zinc Deficiency.....	20
Part VI <i>Angular cheilitis</i> : Nutritional, Diet and Home Remedies In <i>Angular cheilitis</i>	25
A. Nutritional Function to Improve Health.....	25
B. Diet for the Prevention of <i>Angular cheilitis</i>	34
C. Home Remedies in <i>Angular cheilitis</i>	39
Part VII Nutritional Management of <i>Angular cheilitis</i>	46
Reference.....	50

Chapter 1

Introduction

Angular cheilitis presents as an area of inflamed and cracked skin at the angles of the mouth (Zaidan, 2008). *Angular cheilitis* is often found in schoolchildren in Indonesia (Partakusuma, 2016). One type of oral disease that often occurs in the community, especially children when there are nutritional factors is *angular cheilitis* occurs due to the condition of decreased immunity and below nutritional status (Fajriani, 2017). Nutritional deficiency is usually caused by inadequate intake of vitamin B complex, iron and folic acid (Faiz, 2010). This disease can also be caused by vitamin B complex deficiency, blood iron deficiency, folate deficiency, denture sore mouth and other factors such as breathing through mouth, wetting lips with tongue and licking the corner of the mouth with tongue (Murry *et al.*, 2008; Park, 2011; Rakhmayanti *et al.*, 2016). This disease progression is so fast. There for should be no delay in treatment if symptoms of *angular cheilitis* occurred and very clear (Park, 2011).

Nutrition is a major factor that supports our optimal body function and health status (Smolin *et al.*, 2005). WHO estimates that malnutrition children account for 181.9 million (32%) in developing countries. In Central and South East Asia, approximately half of children have a decline in growth, compared to their age (Atmarita, 2006). There is debate about the causes of *angular cheilitis* and many factors suspected, including malnutrition and infection (Murry *et al.*, 2008).

In this globalization era nowadays, society has understood the importance of nutrition for children. Most people have learned about various common diseases related to malnutrition, however not many of them understand about *angular cheilitis*, a disease which can be caused by fungal, and bacteria infection, predisposed by malnutrition. *Angular cheilitis* has other names, *perleche*, *angular cheiolis* and *angular stomatitis* (Yusran *et al.*, 2013).

Oro-dental disease can occur to anyone. Dental and oral diseases can be benign, malignant, painful, can cause redness or not, etc., and dental and oral diseases occur due to decreased immunity conditions and low nutritional status. One type of oral disease that often occurs in the community, especially children, if there is a malnutrition factor is *angular cheilitis*. *Angular cheilitis* is a serious problem due to its rapid development, therefore there should be no delay in treatment if symptoms of *angular cheilitis* have occurred and are very clear. This is not limited to certain age groups, where this condition has affected children and parents. Both children and adolescents can get *angular cheilitis* regardless of sex (White, 2010). Children who suffer from *angular cheilitis* tend to be isolated and do not want to get along because they feel different from their peers and greatly affect a child's confidence (Faiz, 2009).

Angular cheilitis occurs more in children and it is caused by children sensitivity against certain contact agents like toys, foods, sunlight, allergy against medicines, cosmetics and long-term antibiotic treatments. Disease attacking the corners of the mouth is often cause pain when patients experience dry mouth or xerostomia. This disease can also be caused by vitamin B complex deficiency, blood iron deficiency, denture sore mouth and other factor such as breathing through mouth,

wetting lips with tongue and licking the corner of the mouth with tongue (Fajriani, 2017).

Drugs that cause *angular cheilitis* include isotretinoin, sorafenib (antineoplastic kinase inhibitor), and ointments or creams such as neomycin sulfate-polymyxin B sulfate, bacitracin, idoxuridine, and steroids (Park *et al.*, 2011).

Angular cheilitis appears diagnosed with herpes lesions labialis, ulcers, impetigo, and secondary syphilis lesions. Treatment of *angular cheilitis* is by eliminating the etiology factors. Secondary infection must be remembered. If the primary cause is not corrected, the treatment of the infection will not produce a permanent cure (Fajriani, 2017).

Chapter 2

Clinical Overview of

Angular cheilitis

Clinically, *angular cheilitis* can occur in chronic condition, where the corner of mouth or mouth inflamed because of wound infection. Infection that caused this condition is a type of fungi or bacteria. Affected area usually feels pain and healing period depends on the treatment. All ages can be affected by this disease (Fajriani, 2017). Clinical features is characterized by the existence of fissures and erythema on the corners of the mouth, which extended to bottom lip and possibly extended to buccal mucosa. *Angular cheilitis* initial symptom is itchiness on the corner of the mouth and it looks appearance inflamed skin and red spots. The tongue is red and shiny (depapillated glossy red tongue) in patients. *Angular cheilitis* presents as an inflammation at the corner of the mouth. Most cases are caused by a mixture of infective organisms such as *candida albicans*, *staphylococcus aureus*, and beta-hemolytic streptococcus. The condition occurs most frequently in aged individuals with deep labial folds after loss of occlusal height (decreased vertical dimension of occlusion). The deep labial folds become red, sore, and fissured after constant bathing by saliva. In some cases habitual licking of the corner of the mouth may also lead to the development of *angular cheilitis* without deep labial folds (Ilery *et al.*, 2013). After clinical inspection and the extent of the disease is determined, patients can be classified into 3 broad categories : mild (type I), moderate (type

II), or severe (type III) (Warnakulasuriya *et al.*, 1991).

Angular cheilitis or *perleche* is an inflammation reaction on the corner of the mouth, the condition is characterized by cracks and inflammation on both corners of the mouth. This *angular cheilitis* is an inflammatory state in the corner of the lips which may arise bilateral or unilateral. This situation is accompanied by pain, discomfort, sometimes bleeding, and it can interfere with chewing and speaking. *Angular cheilitis* in children can be a serious problem if it is not handled properly. This disease progression is so fast. *Angular cheilitis* the clinical diagnosis of majority of lesions affecting at the corner of the mouth. In children, it is a global issue. *Angular cheilitis* becomes a serious problem due to its rapid development, therefore there should be no delay in its treatment if symptoms of *angular cheilitis* have clearly occurred. *Angular cheilitis* occurs more in children and it is caused by children sensitivity against certain contact agents like toys, foods, sunlight, allergy against medicines, cosmetics and long term antibiotic treatment. Disease attacking the corners of the mouth is often cause pain when patients experience dry mouth or xerostomia. This disease can also be caused by vitamin B complex deficiency, blood iron deficiency, denture sore mouth and other factors such as breathing through mouth, wetting lips with tongue , and licking the corner of the mouth with tongue. *Angular cheilitis* also called *perleche* is a lesion marked with fissures, cracks on corner of lip, reddish, ulceration accompanied by burning sensation, pain and dryness on the corner of the mouth. In severe cases, these cracks can bleed when opening the mouth and cause shallow ulcer or krusta (Fajriani, 2017; Murray *et al.*, 2008).

Tooth and mouth disease can occur in the non-ceratin mucosa and keratinized mucosa, can provide complaints or without complaints, can

be painful or painless, can be a color abnormality, a benign or malignant disorder (Purba, 2011). Mouth disease can affect all ages including children. One example of abnormalities in the oral cavity that is often experienced by children is *angular cheilitis* caused by a lack of nutrition during the growth period (Scully *et al.*, 2010).

Angular cheilitis has another name for *perleche*, *angular cheilosis* and *angular stomatitis*. According to Scully (2004) and BMJ (2019), these lesions are characterized by fissures, erythema and crusting in the corners of the mouth that spread below the lips and possibly extend to the cheek mucosa (Figure 1) (Nesbit *et al.*, 2017).

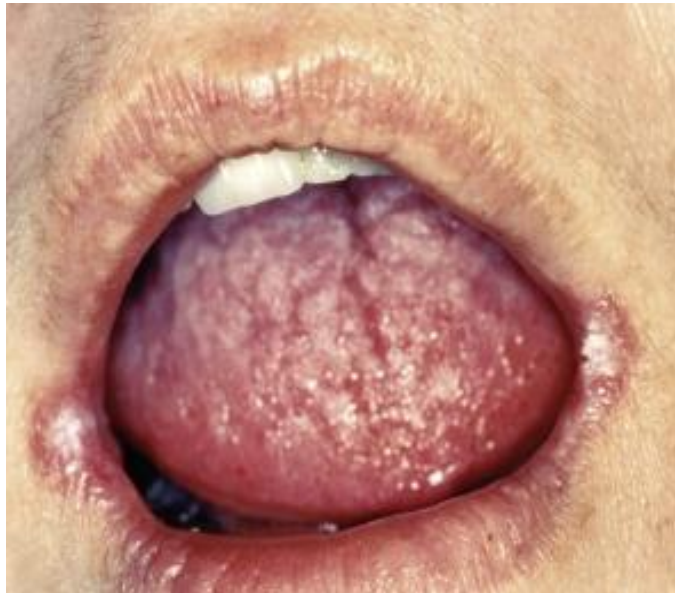

Figure 1 *Angular cheilitis* (Nesbit *et al.*, 2017)

Angular cheilitis is an acute or chronic inflammation of the skin closely with the membrane of mucosa labia from the corner of the mouth (Ilery *et al.*, 2013). Early symptoms *angular cheilitis* is itching in the corners of the mouth and visible appearance of inflamed skin and red spots. At first, this is not dangerous, but it will feel pain in the corners of the mouth and easily bleed due to mouth movements such as laughing or talking. The severity of the inflammation is characterized by angle of mouth cracks and some bleeding when the mouth is opened. In general *angular cheilitis* has the main symptoms of dry lips, discomfort, the presence of scales and formation of fissures (gaps) followed by a burning sensation in the corners of the mouth. Most often as triangular erythema and edema regions in both commissures or can be atrophy, erythema, ulcer, crusting and skin release until recurrent exudation occurs. Long-term reactions, suppuration and granulation tissue occur (Murray *et al.*, 2008).

In *angular cheilitis* associated with nutrition deficiency, *angular cheilitis* is an inflammatory reaction at the corner of the mouth that often begins with mucocutaneous deviation and continues to the skin. *Angular cheilitis* is characterized by diffuse redness, fissure-like form, skin that appears eroded, ulcer, which has a layered surface and is accompanied by subjective symptoms such as burning and pain. *Angular cheilitis* is a serious problem due to its rapid development, therefore there should be no delay in treatment if symptoms of *angular cheilitis* have occurred and are very clear. This is not limited to certain age groups, where this condition has affected children and parents. Both children and adolescents can get regardless of sex. The most frequent ages are decades 4, 5 and 6 (White, 2010).

Oral cavity is one of the small parts of the human body, however oral cavity can describe the state of nutrition from someone. One of the abnormality in oral cavity that often undergo in childhood period that have close relation to the state of nutrition in growing stages is *angular cheilitis* (Ilery *et al.*, 2013). The prevalence of *angular cheilitis* is quite high, especially in Indonesia. Where is the result of calculations carried out by the Faculty of Dentistry, Hasanudin University. This calculation is based on the number of visits recorded since October 2010. It is known that 199 *angular cheilitis* patients with distribution of pediatric patients (<12 years) reached 93.4% (186 patients) and male and female ratio 2.23 : 1.05 (Yusran *et al.*, 2013).

Chapter 3

Predisposing Factors of *Angular cheilitis*

Angular cheilitis (perlèche) is defined by fissures, erythema, and encru stations at the corners of the mouth, and is commonly seen in patients with dental stomatitis and with habitual licking at the corners of the mouth. Etiology is multifactorial and includes mechanical factors, infectious agents, nutritional deficiencies, or inflammatory dermatological conditions. The study of Warnakulasuriya *et al.* (1991) confirms the multifactorial etiology of *angular cheilitis* while nighlighting the varied clinical presentation of the lesions in an Asian population. Diagnosis is made clinically; however, laboratory tests help to identify etiology. Successful therapy is based on identifying and correcting each and all factors of this multifactorial condition (BMJ, 2019). Children are most at health risks from the environment (WHO, 2019).

Angular cheilitis is most often chronic, seen in the older, and due to infective and/or mechanical causes. According to Scully (2013), predisposing factors of *angular cheilitis* are :

- a. Dental appliance or denture-wearing, denture-related stomatitis and disorders that predispose to candidiasis :
- b. Dry mouth
- c. Tobacco smoking
- d. Deficiency states, such as :
 - 1) Deficiency anemia
 - 2) Iron deficiency

- 3) Hypovitaminoses (especially vitamin B)
- 4) Malabsorption states (e.g. Crohn disease) or eating disorders
- 5) Possibly zinc deficiency, but only rarely
- 6) Immune defects, such as in Down syndrome, HIV infection, diabetes, cancer, immunosuppressed people, eating disorders and others.

A premalignant condition of *angular cheilitis* is that commonly involves the lower lip with sparing of the corners of the mouth, is caused by excessive sun exposure. Patients often have persistent dryness and cracking of the lips. In our patient, *angular cheilitis* was the main clinical manifestation of iron deficiency anemia, highlighting the importance of looking for iron deficiency in affected patients without a more obvious cause.

Deficiencies of vitamin B, iron, or folic acid have been reported as predisposing factors. Resolution can usually be achieved with the use of topical antifungal agents (Greenberg *et al.*, 2008; Nesbit *et al.*, 2017). Nutritional deficiencies account for 25% of all cases of *angular cheilitis* and include iron deficiency and deficiency of the B vitamins riboflavin (B₂), niacin (B₃), pyridoxine (B₆), and cyanocobalamin (B₁₂) (Park *et al.*, 2011).

The main cause of *angular cheilitis* in children is nutritional deficiency. Nutritional deficiencies in question are usually caused by a lack of intake of complex B vitamins (riboflavin), iron and folic acid. In causing *angular cheilitis*, every etiological factor especially nutritional deficiency correlates with environmental conditions, the most influential school children are environmental conditions in the family and at school. The environmental conditions in question can be in the form of socio-

economic level of the family, traditional influences in the family, habits or dietary patterns of children and nutrition knowledge (Atmarita, 2006). Malnutrition can be caused by diet, very simple variations in food, heavy maternal workload, infectious diseases, low education and low economic status which will affect people's purchasing power (Deritana *et al.*, 2000). There are several etiological factors of *angular cheilitis* such as fungal infections of *Candida albicans*, nutritional deficiencies, Denture Afternoon Mouth, Avitaminosis, and bad habits. Candidiasis is a red and creamy fungal infection that initially looks like spots formed on a moist surface on the mouth and can cause pain. This condition can cause difficulty swallowing and changing the sense of taste. Candidiasis is more common in young children and parents and also in people with very low immune systems (Murray *et al.*, 2008).

Candidiasis is a red and creamy fungal infection that initially looks like spots formed on a moist surface on the mouth and can cause pain. This condition can cause difficulty swallowing and changing the sense of taste. Candidiasis is more common in young children and parents and also in people with very low immune systems. This can be triggered by antibiotic treatment, which can interfere with the normal activity of oral bacteria. If antibiotics are the etiology, the dentist must immediately reduce the dose or change treatment. Antifungal agents can be used to treat these health conditions. Bacterial infections and mechanical factors as the etiology of often occur in children who have bad habits such as licking the corners of the lips and sucking fingers. This causes saliva to gather in the corners of the mouth and unwittingly contributes to providing the perfect environment for infectious agents to cause *angular cheilitis* (Murray *et al.*, 2008). Local causes include infection with *candida albicans* or *staphylococcus aureus* and allergic

contact dermatitis. Common causes of allergic contact dermatitis include lipstick, toothpaste, mouthwash, cosmetics, sunscreen, fragrance, metals such as nickel, and dental appliances (Park *et al.*, 2011).

The results of the study from Ilery *et al.* (2013) found that the high frequency of children with status under normal nutrition experienced *angular cheilitis* which reaches 84% on the area is caused by numbers nutritional adequacy (RDA) is not fulfilled. The high frequency of children with status under normal nutrition experienced *angular cheilitis* which reaches 84% on the area is caused by numbers nutritional adequacy (RDA) is not fulfilled because of low energy consumption and protein in daily food or called protein energy deficiency (Almatsier, 2010). Demographically, PEM (protein energy malnutrition) in the future children are caused by a typical environment with material, social, and poverty cultural. Marked by sanitation that is notadequate, poor personal hygiene, less income. Data from Research Basic Health 2010 shows that 35.8% of elementary school-aged children who are malnourished, apart from economic factors, lack of knowledge and insightthe community about good nutrition can cause a lack of quality intake their nutrition.

It seems however, that the infection is secondary to a local or systemic predisposing factor. Thus topical chemotherapy of the of the lesions will not produce a permanent cure if the predisposing conditions are not removed (Cawson, 1963; Jorgensen *et al.*, 1970). According to Zaidan (2008) predisposing factors of *angular cheilitis* are :

- a. Vertical dimension of occlusion and lip support.

Epidemiological studies have shown an association between a decreased vertical dimension of occlusion and *angular cheilitis*.

b. Denture stomatitis.

Several studies have shown that *angular cheilitis* occurs more frequently in patients with denture stomatitis. The infection may start beneath the maxillary denture and from that area spread to the angles of the mouth.

c. Carbohydrate consumption.

Direct association between *angular cheilitis* and large intake of carbohydrates has been shown, and it was assumed that a high salivary concentration of glucose predispose to infection, in the angles of the mouth.

f. Avitaminosis.

Avitaminosis may suppress host resistance; lesions will usually be bilateral and often associated with glossitis. Deficiencies of B-vitamins seem to be particularly important predisposing conditions. Thus a decreased plasma concentration of thiamin and riboflavin was demonstrated in patients with *angular cheilitis*.

g. Anemia.

Iron-deficiency anemia (microcytic hypochromic anemia) is the most common of all anemia's. The causes are : - chronic blood loss, such as in menses, menopausal bleeding, parturition, bleeding hemorrhoids, or a bleeding malignant lesion or ulcer in the gastrointestinal tract. It also may develop in patient from a variety of causes that may decrease the rate of absorption of iron, such as subtotal or complete gastrectomy, or in the malabsorption syndromes. An inadequate dietary intake of iron also may be responsible.

Eventhough *angular cheilitis* is related to malnutrition, its pathogenesis involve predisposing factors such as bad habits which allow continuous humidity in the angular area, providing a favorable environment for the growth of microorganisms (Iman, 2016).

Angular cheilitis is an inflammatory state in the corner of the lips which may arise bilateral or unilateral. This situation is accompanied by pain, discomfort, sometimes to bleed, and it can interfere with chewing and speaking. *Angular cheilitis* typical presents as erythema, scaling, fissuring, and ulceration. A wide variety of factors, including nutritional deficiencies, local and systemic factors, and drug side effects, may produce *angular cheillitis* (Park *et al.*, 2011).

In this study of Zaidan (2008) the results revealed that the age range of patients with *angular cheilitis* of (9-70) years which is a wide range because in each group of age there is a possibility to be affected with *angular cheilitis* if the causative and the predisposing factors were present. Nineteen patients (23,1%) were denture weares; the reason for the presence of *angular cheilitis* in the patirnts is that dentures may have both direct and indirect etiological significance. Directly, over closure, decrease in vertical dimension poor lip-support and denture stomatis will predispose for an infection of the angles of the mouth. Indirectly, poor functioning dentures may direct the patient's choice of food to deficient diet, which may result in a state of nutritional deficiency (Zaidan, 2008).

Chapter 4

Angular cheilitis Induced by Vitamin B and Folic Acid Deficiency

Nutritional deficiencies account for 25% of all cases of *angular cheilitis* and include iron deficiency and deficiencies of the B vitamins riboflavin (B₂), niacin (B₃), pyridoxine (B₆), and cyanocobalamin (B₁₂) (Park *et al.*, 2011). Megaloblastic anemia reported for up to 75% of individuals who are deficient in vitamin B₁₂ and folic acid (Greenberg *et al.*, 2008). The effect of vitamin B₁₂ is large enough to cause the onset of *angular cheilitis* (Rakhmayanthie *et al.*, 2016).

Riboflavin (vitamin B₂) was first discovered because it can cure several symptoms of pellagra (Horwitt, 1980). Riboflavin (vitamin B₂) deficiency often is accompanied by a mixed vitamin B a mixed vitamin B complex deficiency due to its role in the metabolism of vitamin B₆ and tryptophan, the latter of which is then converted to niacin (vitamin B₃). It may also present as ocule-oro-genital syndrome, characterized by the following changes : *perleche* or *cheilosis* or *angular cheilitis*, magenta-colored glossitis, interstitial keratitis and corneal vascularization, and scrotal and vulvar lesions (Baron, 2011; Linder, 1992). Generally, riboflavin deficiency will present as redness of the mucous membranes, *angular cheilitis* and magenta-colored glossitis (Wray *et al.*, 1999). Ingredients that contain lots of riboflavin vitamins are sprouts, wheat germ, corn seeds (Linder, 1992). *Angular cheilitis* also is seen in various forms of malnutrition and in patients on total parenteral nutrition (Forbes *et al.*, 1997). For example, patients with anorexia nervosa often present

with *angular cheilitis* and *angular stomatis* (60%), which are sometimes related to riboflavin and other vitamin deficiencies (Strumia, 2005).

Vitamin niacin (vitamin B₃) was discovered in 1867 by Funk (Linder, 1992). This vitamin is contained in many foods such as liver, kidney, meat, fish, chicken, green leaf vegetables, tomatoes, peanuts (Yuniastuti, 2008). Pellagra, the deficiency of niacin (vitamin B₃) and protein, causing the 3 *d*'s (dermatitis, diarrhea, and dementia), can result in glossitis or *angular cheilitis* and has been found to be a more frequent cause of *angular cheilitis* than riboflavin deficiency (Cayer *et al.*, 1945).

Vitamin pantothenic acid (vitamin B₅) is essential for humans, discovered in 1939 by several scientists. In 1950 it was mentioned that this vitamin could cure several skin lesions, including *angular cheilitis*. As with other B vitamins, the most concentrations are found in sprouts of grains and nuts, yellow eggs, liver, kidneys, heart and soybeans (Linder, 1992). A single case study of patients with *glossitis* and/or *cheilosis* refractory to other vitamin B nutrients demonstrated the effectiveness of treatment with calcium pantothenate, a source of vitamin B₅ (pantothenic acid or pantothenate) (Field *et al.*, 1945).

The name vitamin pyridoxine (vitamin B₆) was given by Szent-Gyorgy in 1934 and isolated in 1938, this vitamin can cure *angular cheilitis*. There are additional needs for pregnant/ lactating women, contraception, hyperthyroidism, syndromes, carpal tunnel, high protein diet, stress, hyperoxaluria. Ingredients that contain lots of vitamin pyridoxine are liver, soy flour and bananas (Linder, 1992). Pyridoxine (vitamin B₆) deficiency causes *angular cheilitis*, *glossitis*, *seborrhealike* changes around the mouth, eyes, and nose. It often occurs in alcoholics and may occur in patients on medications that impair vitamin B₆ metabolism, which includes cycloserine, isoniazid, hydralazine

hydrochloride, oral contraceptives, D-penicillamine, and levodopa (when taken without carbidopa) (Felder *et al.*, 1988).

Vitamin Biotin (vitamin B7/vitamin H) was discovered by du Vigneaud, Kogl, and friends, and this vitamin essential for humans (Linder, 1992), Biotin vitamin deficiency associated with *angular cheilitis*. Patients may present with *angular cheilitis* along with other symptoms such as dry eyes and alopecia (Forbes *et al.*, 1997). Biotin deficiency causes a variety of common symptoms, involving the skin and mucous membranes, tendons, general fatigue and so on. food sources of vitamins biotin are yeast, liver, egg yolk, tomatoes, soybeans, rice with bran (Linder, 1992).

Vitamin B₁₂ (cyanocobalamin) is essential for humans, discovered in 1948 by several scientists in the field of pharmacology from the USA and England. Only vitamin B₁₂ with vitamin D is not found in plants, fruit and vegetables; therefore only this vitamin tends to not be on a vegetarian diet (strict vegetarian) because these factors are found in eggs, dairy products, and meat, especially liver. Food ingredients for seaweeds and food ingredients from fermented soybeans, contain a little (2-7 µg / 100 g, dry) (Linder, 1992).

Vitamin B₁₂ has a very large role in the process of DNA synthesis, as without vitamin B₁₂, folic acid can not be transformed into its active form so that the group of 5-methyl tetrahydrofolate can not help the process of formation of methylcobalamin which will give the group methyl to the homocysteine for the methionine synthase, which form methionine and tetrahydrofolate. Tetrahydrofolate is a precursor for folate cofactors required in the synthesis of DNA cell to form purine and thymine. Similarly, in the formation of the blood cells, megaloblastic anemia due to vitamin B₁₂ deficiency lies in the role of vitamin B₁₂ in a

reaction that is influenced by the this cycle of methionine synthase (Guyton *et al.*, 2006).

Vitamin B₁₂ functions as a cofactor in enzymatic reactions required in the synthesis of DNA. If there is any deficiency of vitamin B₁₂, the process of DNA synthesis would be disturbed, resulting in an interruption in the process of mitosis so that the cells do not mature and the formed cell may be dysfunctional (Yagiela *et al.*, 2004). Vitamins B₁₂ has very large role in the process of DNA synthesis, as without vitamin B₁₂ can not be transformed into its active form so that the group of 5-methyl tetrahydrofolate can not help the process of formation of methylcobalamin which will give the group methyl to the homocysteine for the methionine synthase, which form methionine and tetrahydrofolate. Decreased vitamin B₁₂ (cyanocobalamin) levels make patients vulnerable to the development of *angular cheilitis*. It commonly is associated with malnutrition, alcoholism, and pernicious anemia. Other causes include terminal ileum resection or disease (common in Crohn disease), postgastrectomy states, chronic pancreatitis, strict vegan diets, and infection with *Diphyllobothrium latum*. Vitamin B₁₂ levels are changed by cholestyramine, colestipol, *p*-aminosalicylic acid, and potassium chloride (Felder *et al.*, 1988).

Contrary to vitamin B₁₂, folic acid is widely found in plant-based ingredients, especially if it is raw or relatively low in process, this vitamin cannot stand the heat. Complete grains, many yeast preparations and liver contain a lot of folic acid (Linder, 1992). Folic acid deficiency often presents with vitamin B₁₂ deficiency and is characterized by stomatitis, glossitis, and megaloblastic anemia. Folic acid supplementation is affected by methotrexate, phenytoin, phenobarbital, primidone, oral contraceptives, and triamterene. Chronic alcoholism,

tropical and celiac sprues, pancreatic diseases, malnutrition, and other malabsorption syndromes can produce multinutrient deficiencies leading to folate, vitamin B₁₂, and iron deficiencies, which can lead to *angular cheilitis* (Felder *et al.*, 1988).

Folic acid has an important role formation reaction of purine and thymine, which are critical components forming the DNA (Guyton *et al.*, 2006). If there is any deficiency of vitamin B₁₂, folic acid, or both, the process of DNA synthesis would be disturbed, resulting in an interruption in the process of mitosis so that the cells do not mature and the formed cell may be dysfunctional. These cells are fragile, easily (Yagiela *et al.*, 2004). Broken and have a shorter life than normal cells (Guyton *et al.*, 2006). Changes will clearly be seen easily on cells that divide rapidly, such as the cells in the bone marrow, will be an interruption in the process of hematopoiesis, and led to the interrupted formation of red blood cells with the characteristics of macrocytic cells with an oval shape that is irregular indicating the cells are not matured (Yagiela *et al.*, 2004).

Chapter 5

***Angular cheilitis* Induced by Iron and Zinc Deficiency**

Anemia is a risk factor for the occurrence of *angular cheilitis*. Further research on soft tissue disorders in the oral cavity is required to add information about oral diseases in the community as well as their managements. Anemia is a lack of hemoglobin in the blood caused by deficiency of nutrients required for the formation of hemoglobin (Partakusuma, 2016). Function of hemoglobin is carrying oxygen from the lungs to all cells and return to the lungs with carbondioxide. Hemoglobin consists of heme which is component that contains of iron, which is attached to the globin protein. A small portion of iron (about 5%) contained in the muscles as myoglobin, about 1% associated with enzyme systems, and the rest is stored in the body (Gibson *et al.*, 2005).

According to World Health Children (WHO), approximately 150 million (26.7%) of children under age 5 in some developing countries in the world were malnourished by weight at his age. These nutritional deficiencies occur due to lacking of the intake of nutrients. Iron deficiency anemia is the most frequent type of anemia occurs. The percentage is about 30% of the world's population, 500 million cases worldwide (Greenberg *et al.*, 2008). The global prevalence of preschool children who suffer from anemia in 2008 according to WHO was 47% of the whole preschool children in the world.

Prevalence of iron deficiency anemia in Indonesia is still in a high rate. Basic Health Research (known in Indonesian as *Riset Kesehatan Dasar*) showed that 60% of iron deficiency anemia occurred in women, in child bearing age and 59% occurred in pregnant women. The high incidence of anemia in Indonesia shows that a low intake of iron or low iron bioavailability, and is unable to meet increased of iron requirements (Cusick *et al.*, 2008). In Indonesian the majority of anemia is caused by lack of iron and is called iron deficiency anemia. Iron deficiency anemia is a predisposing factor for candidosis that can therefore mediate *angular cheilitis*. Iron deficiency anemia is affecting more than 30% children of the global population (Zimmermann, 2006).

Malnutrition is a major cause of *angular cheilitis* in the third world countries. The most common anemia is iron deficiency anemia. Iron is needed for the growth and differentiation of all cells. Iron plays a role in oxygen transport, electron transfer, and serves as a cofactor in many enzyme is many enzyme systems, such as peroxide-generating enzymes and nitrousoxyde-generating enzymes that essential to the proper functioning of the immune cells (Shin-Yu-Lu, 2016). Chronic iron deficiency can cause koilonychia, glossitis, and cheilosis with fissuring. The mechanism for *angular cheilitis* in this patients has not been fully elucidated, but it has been suggested that iron deficiency decreases cell-mediated immunity, thereby promoting mucocutaneous candidiasis (Higgs *et al.*, 1972).

Ayesh (2018) mentions that a 20-year-old woman had a 4-month history of painful red erosions around the mouth. She had no dysphagia or fatigue and no history of diarrhea, gluten intolerance, or *diabetes mellitus*. An antifungal-antibacterial ointment prescribed by her dentist had provided no relief. Physical examination revealed an erosive

dermatitis and fissures at the angles of the *angular cheilitis* or *perleche* is an inflammatory condition characterized by erosive inflammation at one or both angles of the mouth (Figure 2).

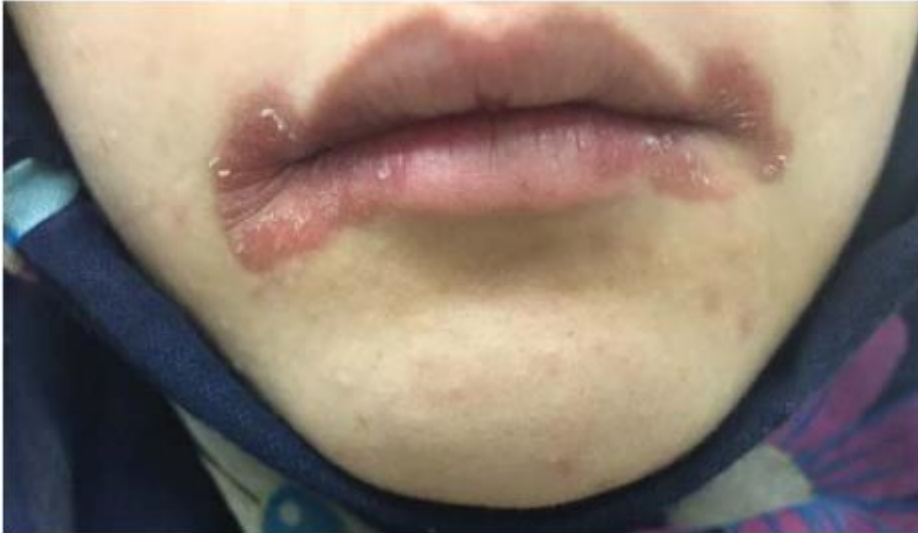

Figure 2 The Erosive Dermatitis and Fissures at *angular cheilitis* (Ayesh, 2018)

The oral cavity was normal, with no evidence of oral thrush or ulcers. Hematologic testing revealed the following:

- a. Hemoglobin 8.0 g/dL (reference range for females 12.3–15.3)
- b. Serum ferritin 1.3 ng/mL (15-200)
- c. Vitamin B₁₂ and folate levels were normal, and tests for antitissuetransglutaminase and antinuclear antibodies were negative.

Based on these results, the diagnosis was *angular cheilitis* from iron deficiency anemia. Treatment with oral ferrous gluconate 300 mg twice daily cleared the cheilitis, and after 4 weeks of this treatment, the hemoglobin level increased to 9.8 g/dL, the serum ferritin increased to 7 ng/mL, and the reticulocyte count increased to 2.6%. She was advised to continue taking oral iron tablets for another 3 months until the hemoglobin level reached 12.0 g/dL. During 2 years of follow-up, she had no recurrence of *angular cheilitis*, and her hemoglobin and serum ferritin levels remained normal. Ferrous gluconate was her only medication from the time of her diagnosis (Ayesh, 2018).

There are no relationships between anthropometric status, oral hygiene and *angular cheilitis* ($p>0.05$). However there is a relationship significant, significant relationship between anemia and *angular cheilitis* ($p<0.05$). Logistic regression test showed that anemia is a risk factor on the occurrence of *angular cheilitis* (Partakusuma, 2016).

Females were affected with *angular cheilitis* more than males, which is in agreement with the results of other investigators. Also females were more affected with iron deficiency anemia than males. This may result from blood loss such as in menstrual or menopausal bleeding, and parturition (Zaidan, 2008).

Zinc minerals are microminerals that are everywhere in human tissue and are involved in the functioning of various enzymes in the metabolic process. The most significant effect is in the metabolism, function and maintenance of the skin. Plays an essential role in all cells, and if zinc deficiency will cause extensive changes (Linder, 1998). Lack of the essential mineral zinc is characterized by the triad of diarrhea; alopecia; and dermatitis manifesting as eczematous and erosive changes around the mouth as well as the acral and genital areas. *Angular cheilitis*,

glossitis, and *pustular paronychia* also are seen. In fact, *angular cheilitis* is common early sign of acrodermatitis enteropathica and heralds relapse in these patients (Baron, 2011).

Chapter 6

Angular cheilitis :

Nutritional, Diet and Home Remedies in Children

A. Nutritional Function to Improve Health

Health that is most concerned by WHO (World Health Organization) is the health of pregnant women and children. For this reason, both of them are given details for the problem of nutrition intake and daily food consumption. School-aged children around 7-13 years old are the second fastest growth period after infancy. Where optimal health will produce optimal growth as well. Nutritional intake is needed to fulfill both of them, physical and mental children. Because physical and mental is something different but interrelated. Foods that are rich in nutrients greatly affect the growth of the brain and other organs needed by children to achieve optimal educational outcomes, for which the family is the first party to pay attention to their child's nutritional intake. Family knowledge of nutrition greatly influences the nutritional status of children. The higher the level of body activity, the more nutrients and energy will be needed, elementary school age children or school age are ages who like to play. It's nice to spend time learning about the environment. For this reason, there is a need for nutrition and a lot of energy intake to support physical activity. The difficulty to consume nutritious food is a challenge that needs to be faced by parents. For that knowledge about child nutrition is highly recommended to learn it. The appetite for school-age children is unpredictable, what appetite he is currently enjoying, changes in attitudes toward food are influenced by

several factors, one of which is outside influence. At this time the mother's attention to the influence of food consumption patterns seems to be encouraged. School-age children are very difficult to be able to consume foods that are needed for growth. The criterion of food that is much preferred by children of this age is foods that contain lots of sugar and have bright colors so that it attracts children to consume them. There are two main factors that influence a child's optimal growth and development process, namely internal factors and external factors. Internal factors are factors that exist within the child itself, both innate and acquired factors. External factors are factors that exist outside or originate from outside the child, including the physical and social environment and the physical needs of the child. In addition to these two factors, factors that play a role in the child's growth process can be determined by family, nutritional status, culture, and playmates. The family should support the process optimal growth and development. Children's nutritional status can be determined by the level of consumption or quality of food. Food quality is determined by the nutritious substances needed by the child. There are two kinds of problems in child development, namely over nutrition and under nutrition. As a result of poor nutritional status, it can cause disease. The community environment in this case the care and habits of a society can affect the growth and development of children. The procedures and habits imposed by the community are not always in accordance with hygiene and health conditions. Playmates and schools also play a role in influencing the food consumed by children. When they interact with playmates or school friends, the food or snacks chosen are usually the same as those chosen by close friends or the surrounding environment. Living things need food to sustain their lives. Food consists of parts in

the form of chemical bonds or inorganic elements called food substances or nutrients. Humans get their food ingredients in the form of food ingredients. Which comes from plants or animals. One type of food cannot fulfill all of the body's needs for various food substances, because each food ingredient contains different kinds of foods and many (Ari Agung, 2017).

Based on "the cause of malnutrition" (Unicef, 1998), it can be concluded that nutritional problems at one stage of life will affect the next stage of life, so that solving nutrition problems must be comprehensive for all stages of life. The direct cause of nutritional problems is an imbalance between food intake and nutrients that cannot be utilized optimally by the body due to impaired absorption as a result of infectious diseases (Yulica, 2008). Nutrition is an important component for children's health. The growth and development experienced by children makes them need good nutrition in terms of protein, energy and other nutrient components. It also makes them vulnerable to nutritional deficiencies and growth disorders. A diet that starts from childhood can affect their health further. In childhood, giving poor nutrition can lead to failure to thrive, obesity, and diseases related to nutritional deficiency. The long-term consequences that can be caused are the increased risk of degenerative diseases later in old age.

According to Arisman (2007) nutritional problems generally occur in school-age children are anemia due to iron deficiency. This situation occurs because of too little iron content in food, especially in children who consume too much milk, thereby reducing the desire to eat other foods. Growth failure is usually caused by lack of nutritional intake. In addition to failure to grow, lack of nutrient intake can also cause anemia and make children vulnerable to infection.

Nutrition problems in elementary school children are still quite alarming. This can be seen from several studies conducted on elementary school age children in Indonesia. Primary school-aged children in this case are children aged 7-12 years. In the research conducted by Dr. Saptawati Bardosono, a nutritionist from the University of Indonesia, in five elementary schools in Jakarta, it was found that 94.5% of children received nutritional intake below the number.

Long and severe infections are also closely related to nutritional problems in the form of malnutrition. Infection can cause malnutrition. A child who has an infection needs more nutritional intake than usual. While some of the symptoms experienced during infections such as diarrhea and no appetite make nutrition intake difficult. Conversely, malnutrition can also cause individuals to be susceptible to infection. Our immune system is supported by protein, iron, vitamins and several other micronutrients. If the nutrient intake is lacking, the work of the immune system is not optimal.

The socio-economic level affects the ability of the family to fulfill nutritional needs, the choice of additional foods, healthy living habits, the quality of environmental sanitation and the frequency of someone suffering from an infectious disease. Nutritional consumption of food in a person can determine the achievement of the level of health, or often called nutritional status. If the body is at the optimum level of nutritional health, where tissue is saturated by all nutrients, then it is called optimum nutritional status. In this condition the body is free from disease and has the highest endurance. If the nutritional consumption of food in someone is not balanced with the needs of the body, there will be fatigue due to nutrition (malnutrition). Children with primary school age can determine the food they like. Food given to children of primary school age is

determined based on body weight, age and children's activities. Boys generally do more physical activity than girls, so food intake that contains more energy needs to be increased. Whereas girls at primary school age begin to enter menstrual age, so they need more protein and iron.

Breakfast for children of primary school age is very important considering activities in the school that involve physical and concentration learn. The primary school environment generally has a lot of snacks. Many children like snacks that only contain carbohydrates and salt. These foods will only make a child quickly full and reduce the child's appetite.

Efforts to improve the nutrition of school-age children can pay more attention to the following matters (Beck, 2014) :

- a. Increase food security, namely the ability of families to meet the food needs of all family members in sufficient quantities and good quality.
- b. Improve the quality of parenting patterns, namely the ability of the family to provide time, attention and support for children in order to grow and develop optimally both physically, mentally and socially.
- c. Improve family education, knowledge and skills.

Nutritional needs in the body of each individual are very important to strive for. Efforts to increase nutritional needs can be done by eating balanced foods perfectly healthy by being balanced with a clean living situation for each individual. This must be done every day, because without every day the human body can get sick due to decreased body immunity.

A well-chosen daily meal will provide all the nutrients needed for normal bodily functions. Conversely, if the food is not chosen properly, the body will experience a lack of certain essential nutrients. Essential nutrients are nutrients that must be imported from food. To live and improve the quality of life, everyone needs a variety of nutrients, namely carbohydrates, proteins, fats, minerals and water in sufficient quantities, not excessive and not lacking. When grouped, there are three functions of nutrients in the body (Ari Agung, 2017), namely :

a. Giving Energy

Nutrients that can provide energy are carbohydrates, fats, and proteins. Oxidation of these nutrients produces the energy the body needs to move.

b. Body Tissue Growth and Maintenance

Proteins, minerals, and water are parts of the body's tissues. Therefore, it is necessary to form new cells, maintain, and replace damaged cells. In this third function nutrients are called builder substances.

c. Regulating Body Process

Proteins, minerals, water and vitamins are needed to regulate the body's processes. Protein regulates water balance in cells. Minerals and vitamins are needed as regulators in oxidation processes, normal functions of nerves and muscles and many other processes that occur in the body.

According to Pudentiana *et al.* (2017) essential nutrients for optimal health are :

1. **Macronutrients**

Macronutrients consist of three types of substances, namely carbohydrates, proteins, and fats.

- a. **Carbohydrates** and **fats** provide energy for growth and physical activity. During periods of rapid growth, there is an increase in appetite, and children tend to eat continuously. When growth slows down, appetite decreases and children eat less when eating. The brain needs energy to function properly and hence relevant and critical glucose intake. Cognitive tasks require regular intake of glucose to the brain to improve cognitive function and improve memory and mood.
- b. **Protein.** Proteins build, maintain and repair body tissues, especially important for growth. It's important that parents encourage children to eat two to three servings of protein every day. A good source of protein for children is in meat, fish, poultry, milk and processed foods. Protein is needed by the body as a builder, regulator and fuel substance.
 - 1) Builder substance, protein is a new tissue-forming material in the body.
 - 2) Regulatory substances, proteins play a role in regulating various systems in the body.
 - 3) Fuel, protein will be burned when the body's energy needs cannot be met by charcoal and fat hydrates.

- c. **Essential fatty acids.** Unsaturated fatty acid deficiencies will affect the performance of school-age children to be negative. Studies of essential fatty acid supplementation prove significantly related to difficulties with spelling, writing and written expressions.
- d. **Fat.** In general it can be said that fat fulfills basic functions for humans, namely:
- 1) Become an energy reserve in the form of fat cells. 1 gram of fat produces 9.3 kcal.
 - 2) Fat has cellular functions and structural components in cell membranes that are related to carbohydrates and proteins in order to run the flow of water, ions and other molecules, out and into cells.
 - 3) Supports the function of organic compounds as signal transmitters, such as prostaglandins and steroid hormones and bile glands.
 - 4) Being a suspension for vitamins A, D, E, and K that are useful for biological processes.
 - 5) Serves as a shock barrier to protect the body from unfriendly outside temperatures.

2. Micronutrients

Micronutrients are nutrients that are needed in small amounts but are needed by the body to grow and develop every day. Which includes micronutrients are:

- a. **Vitamin.** Vitamins can be grouped into two types, namely water-soluble vitamins (vitamin B and vitamin C, and types of vitamins that are not soluble in water (vitamin A, vitamin D,

vitamin E, and vitamin K).

- 1) Vitamin A, is a vitamin that plays a role in the formation of a good sense of vision, especially at night, and as one of the components of the eye pigment in the retina. In addition, vitamin A also plays an important role in maintaining healthy skin and body immunity.
- 2) B-complex vitamins, usually found together in the same food ingredients, are vegetables and seeds. In the pill called B-complex there are 11 types of vitamins, namely thiamin, riboflavin, niacin, pyridoxine, biotin, PABA, inositol, pantothenic acid, folic acid, choline and vitamin B₁₂. Most members of vitamin B-complex known to function within the co-enzyme. Physiological functions that have been known to require vitamins are as follows :
 - (a) Health of connective tissue matrix substances
 - (b) Epithelial integrity through the health of the adhesive between cells
 - (c). Mechanism of immunity in the framework of the body's resistance to various attacks of diseases and toxins.
 - (d) Decreasing cholesterol levels and
 - (e) Required for the growth of bones and teeth

The prevalence of *angular cheilitis* in 6-18 years old children in Muhammadiyah Orphanage Bandung was moderately high, most of them were having iron, vitamin B₁₂, and folate deficiencies (Rakhmayanti *et al.*, 2016). Some reports indicate that there is a link between nutritional deficiency with *angular cheilitis*. Research conducted by Zaidan in Baghdad 35.3% of 82 patients affected by

angular cheilitis had nutrition deficiencies, especially iron, vitamin B₁₂, and folic acid (Faiz, 2010). *Angular cheilitis* associated with lack of nutrition is often encountered in the first and second decade of life.

The result of the research showed that 50 children were below malnutrition. Meanwhile, the number of occurrence of *angular cheilitis* showed 42 children (84%) in the landfill (TPA) of Sumompo. Therefore, there is a significant relationship between the states of nutrition of a child with the occurrence of *angular cheilitis* (Itery *et al.*, 2013).

B. Diet for the Prevention of *Angular cheilitis*

The higher the level of family food security, the better the care of children and families, so that more and more use of existing health services. During school age, children use biological functions to find things in their lives. At this time it can be mentioned as a period of oral (mouth), because the mouth is seen as a source of pleasure and is a tool for exploration and learn. At the age of 7-9 years, growth will continue to run even though not as fast as when he was a baby. The meal schedule must be adjusted to when the child is in school. Children should be provided with bread or other food to eat during recess. Children need a large portion of food due to more needs, because of increasing body weight and activities carried out. Foods that can be served daily consist of (Beck, 2014) :

- a. Vegetables : can be served 3-5 times/day. Once served it can be combined with raw vegetables.
- b. Fresh fruit that cooks trees.
- c. Bread, cereal or pasta 6-11x / day.
- d. Contains 2-28x/day, 345 grams of cooked meat or fish, eggs

and beans.

The menu presentation can be done at least 2-3x / day with, ie morning, afternoon and evening, such as :

a. Morning Menu

- 1) Rice porridge or bread mixed with butter or margarine
- 2) Eggs, meat or fish.
- 3) 1 glass of milk.

b. Lunch menu

- 1) Rice
- 2) Meat, chicken, eggs, tofu and tempeh.
- 3) Vegetables such as tomatoes, spinach and carrots.
- 4) Fruit such as bananas, apples, papaya, oranges, and pears.
- 5) 1 cup of milk

c. Afternoon Menu

- 1) Rice or bread polished with margarine or butter
- 2) Meat, chicken, tempeh and tofu.
- 3) Fruit or pudding.
- 4) 1 cup of milk.

Treatment of iron deficiency anemia, in addition to providing iron supplementation (if the doctor considers this necessary), the child must also be given and accustomed to eating foods that contain a lot of iron, such as: green vegetables, some fruits, beans, mashed potatoes, eggs , fish and meat. Meanwhile, some milk is replaced with orange juice. Although it does not contain iron, orange juice is rich in vitamin C which can help iron absorption (Arisman, 2007). Not one type of food contains all nutrients, which can make a person to live healthy, grow and be

productive. Therefore, everyone needs to consume a variety of foods. Various foods are very beneficial for health,

Everyone cares about food to maintain their survival. Food contains substances that the body needs, to obtain energy to maintain the continuity of processes in the body, to grow and develop, and to carry out daily activities. Among various types of foodstuffs, some are rich in nutrients, some are nutrient-poor. Generally there is no complete food containing all nutrients in sufficient quantities for the body. Therefore, humans need various kinds of food to ensure that all the nutrients needed by the body can be fulfilled in sufficient quantities.

The *angular cheilitis* treatment depends on its etiology. *Angular cheilitis* caused by vitamin B deficiency should be treated by providing vitamin B complex supplement or multivitamin that contain vitamin B. However, deficiency of one type of vitamin is usually followed by lack of other nutritional deficiency, hence in the treatment, multivitamin administration is more effective than vitamin B complex alone. Reported treatment of disease caused by vitamin B₁₂ with vitamin therapy can be healed in 3 weeks. Antimicrobial administration on patients with *angular cheilitis* caused by nutritional deficiency is only shortened the healing time. Because most of the infection that occur can heal itself without antimicrobials, body's defense system should be maintained or increased by administering vitamin supplements or multivitamins (Morison, 2003).

The high frequency of children who experience *angular cheilitis* with nutritional status thin and very thin because of it the main etiologic fact of *angular cheilitis* in childhood is nutritional deficiency (Decker, 2006; Faiz, 2007; Skinner *et al.*, 2005). Nutritional deficiencies can cause a decrease in the child's immune system so that it is easily attacked by viruses and bacteria.

Nutrition is a process of organisms using food consumed normally through the process of digestion, absorption, transportation, storage, metabolism and expenditure of substances that are not used to maintain life, normal growth and function of organs, and produce energy. Nutrition is all the intake foods that required for the body to become health, it contains balance carbohydrate, protein, fat, vitamin and mineral. Good nutrition is characterized by a condition where the intake of nutrients is suitable for use in bodily activities (Ilery *et al.*, 2013).

Diet nutrition management is most important thing is to maintain a healthy body so that the immune system is maintained and not susceptible to disease and to eat foods that are nutritionally balanced and needed by the body. Besides that we also undertake maintenance of oral hygiene by brushing your teeth (Fajriani, 2017). Nutrition, diet and oral health have strong association especially for children who are in the growth and development phase. Healthy and adequate nutrition play vital role to support oral health in children.

Several research showed that children with nutritional status were less likely to suffer *angular cheilitis* 1.96 times greater than children who have a good nutritional status. The inflammation severity is characterized by cracks on corner of the mouth and some bleeding when the patient's mouth opened in *angular cheilitis* associated with nutritional deficiencies can be seen the depletion of tongue papillae (depapillated tongue) due to iron deficiency.

1. Foods to be Taken

Prevention of *angular cheilitis*, good food is taken are (Ranjan *et al.*, 2016) :

- a. Vitamin B₂ (riboflavine). Major food sources include milk and dairy products, cereals, meats (especially organ meats) and some green leafy vegetables
- b. Vitamin B₃ (niacin). Major food sources include peanuts, rice, bean, liver, kidney, food yeasts, avocado, fish, eggs and lean meats
- c. Vitamin B₆ (pyridoxine). Major food sources include yeast, brown rice, sunflower seed, rice, soya beans, nuts, egg yolk, bananas, liver, wheat germ, fish, chicken, potatoes, cauliflower, cabbage and avocados
- d. Foods rich in iron cabbage, kale, eggs, spinach, fortified cereals, figs
- e. Foods rich in zinc, peanuts, chocolate, pumpkin seeds, wheat-germ

2. Foods to be avoided

Food that must be avoided in the prevention of *angular cheilitis* (Ranjan *et al.*, 2016) are :

- a. Refined and processed foods, spicy foods and fatty foods
- b. Foods high in sugar and salt

C. Home Remedies

Home Remedies in overcoming *angular cheilitis* (Ranjan *et al.*, 2016) are :

- a. Soak your lips in salt water for few minutes this can be helpful as it hastens the healing time
- b. Apply honey or lemon to lips which will be very helpful
- c. Drink lots of water can help you better cure the illness. This will work on your dry and chapped lips. Drink about 10 to 12 glasses of water every day
- d. Apply aloe vera gel on the cracked parts of mouth can help you ease the pain
- e. Use moisturizers to help prevent dryness

According to Anonymous (2019) home remedies for *angular cheilitis* are :

1. **Castor Oil.** Castor oil is another good remedy. It helps tone down *angular cheilitis* by minimizing pain and inflammation due to its anti-inflammatory properties. Additionally, castor oil can keep the skin around the mouth from getting dry. Management of its use is :
 - a. Simply apply castor oil to the affected area near your mouth several times a day.
 - b. Alternatively, mix ½ teaspoon of castor oil and 2 drops of tea tree oil. Use a cotton ball to apply it on the corners of your mouth. Wait 30 minutes before rinsing it off with cool water. Repeat twice a day.

2. **Aloe vera.** Another speedy and effective cure for *angular cheilitis*. How to use *aloe vera* to treat *angular cheilitis*, can be seen in Figure

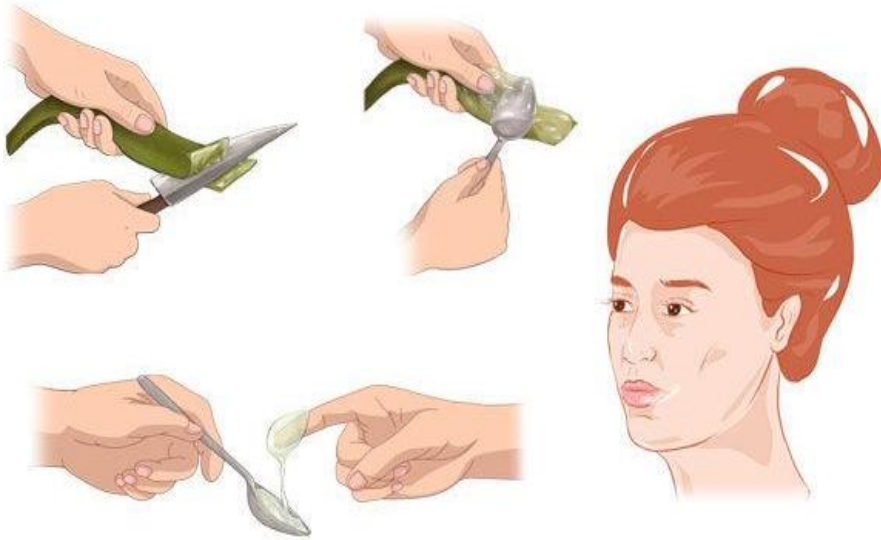


Figure 3 How to use *aloe vera* to treat *angular cheilitis*
(Anonymous, 2019)

Aloe vera has antiseptic, antifungal and anti-inflammatory healing properties, thus making it effective against fungi and a wide range of bacteria. It helps alleviate the pain and inflammation that you have to deal with due to angular cheilitis. It also helps moisturize the dry and damaged skin on the corners of your mouth.

Management of extract the gel from an *aloe vera* leaf use is :

- a. Put the gel in the refrigerator for 30 minutes.
- b. Rub the cool gel gently on the corners of your mouth.
- c. Let it dry for 15 to 20 minutes before rinsing it off with cool water.
- d. Use this remedy 2 or 3 times a day, until the skin at the corners of your mouth heals completely.

3. Yogurt.

Yogurt is good remedy to treat *angular cheilitis*. It contains active bacteria cultures, or probiotics, that help restore the natural balance of bacteria in the body. This in turn helps fight this irritating skin condition. It helps moisturize the skin to promote healing. Management of its use is :

- a. Apply plain, unsweetened yogurt to the corners of your mouth before going to bed. Leave it on overnight and rinse it off with lukewarm water the next morning. Repeat daily for 7 to 10 days or until your condition heals.
- b. Also, include plain yogurt in your diet.

4. Coconut Oil.

Another effective remedy to treat *angular cheilitis* is coconut oil. Due to its antimicrobial properties, the oil prevents the growth and spread of pathogens, and helps fight the infection. Coconut oil also acts as a moisturizer to reduce the dryness of the skin and the resulting pain and irritation. Management of its use is :

- a. Apply some extra-virgin coconut oil on the affected areas. Repeat 3 or 4 times a day.
- b. Alternatively, mix equal amounts of extra-virgin coconut oil and lemon juice. Apply it on the affected area, wait 15 minutes and then rinse it off using lukewarm.

5. Tea Tree Oil.

Tea tree oil has antifungal, antibacterial and antiviral properties that are of great help in the treatment of different skin-related problems, including *angular cheilitis*. Apart from treating microbial infections, it

also reduces inflammation and pain. Management of its use is :

- a. Dilute tea tree oil by adding 3 parts water to 1 part tea tree oil. Dip a cotton ball in the diluted oil and apply it on the affected area, 3 times a day for up to 1 week.
- b. Another option is to mix two drops of tea tree oil in 2 or 3 tablespoons of petroleum jelly. Apply on your sore and leave it on for 30 minutes or more, then rinse it off. Do this a few times a day for a week or until the condition heals completely. Store the remaining mixture in a small jar.
If you do not have tea tree oil, you can use oil of oregano or neem oil in the same way. Grapefruit seed extract can also help heal *angular cheilitis*, especially if it is caused by fungal infection.

6. Honey.

Honey works as a great moisturizer for skin, and it also has healing and antibacterial properties to treat *angular cheilitis*. It can effectively destroy infection-causing pathogens. It also provides relief from the pain and agony caused by this skin problem. Management of its use is :

- a. Apply some local honey or manuka honey on the affected area, several times a day for 1 week.
 - b. Alternatively, melt $\frac{1}{4}$ teaspoon of beeswax. Mix in $\frac{1}{4}$ teaspoon of olive oil and $\frac{1}{2}$ teaspoon of honey. Transfer the contents to an airtight container. Apply a small amount of this cream on the corners of your mouth. Allow it to sit for 15 to 20 minutes before rinsing it off with cool water. Repeat once or twice daily.
-

7. Garlic.

Garlic has enzymes that help fight bacterial, viral and fungi agents that can cause this irritating skin problem. Plus, it acts as an anti-inflammatory and reduces swelling and pain. Management of its use is :

- a. Mince a clove of fresh garlic and add 1 teaspoon of raw or manuka honey to it. You can also add ½ teaspoon of coconut oil. Apply the mixture on the affected areas. Leave it on for 10 to 15 minutes before rinsing it off with lukewarm water. Repeat 3 to 5 times a day. There will be a slight burning sensation in the beginning.
- b. Also, eat a few raw garlic cloves daily to boost your immunity and fight the infection.

8. Bee Propolis

Bee propolis, the sticky resin that bees collect from trees and vegetables, is another effective treatment for angular cheilitis. Bee propolis is rich in antibiotic and antifungal properties that help get rid of a host of skin conditions, including *angular cheilitis*. Bee propolis is also full of important nutrients like amino acids, vitamins, minerals, trace elements, enzymes or coenzymes, and fatty acids that help fight infection and soothe the skin. Management of its use is :

- a. For external use, opt for a propolis powder, spray, ointment or cream that you can easily find in the market. Always follow the instructions on the label.
- b. Can opt to take propolis capsules or tablets. The typical dosage is 500 mg, once or twice per day with food. Always consult your doctor before taking supplements.

9. Fight Nutritional Deficiency

One of the major causes of *angular cheilitis* is a deficiency of vitamin B, especially low levels of B₂ or B₁₂. Also, zinc and iron deficiencies can cause this problem. Hence, nutrition may hold the key to treating this condition. Eat a well-balanced diet so that your food provides all the essential nutrients that your body needs. Also, be sure to get plenty of vitamin B, zinc and iron in diet, as follows :

- a. Some fruits and vegetables that are good sources of vitamin B include spinach, tomato, carrots, green leafy vegetables, and whole grains. Also, drink a cup of warm milk or water mixed with 1 tablespoon of blackstrap molasses daily. Blackstrap molasses is a nutritional powerhouse rich in essential vitamins and minerals that your body needs.
- b. Some good sources of zinc are eggs, oysters, crab, lobster, pulses, baked beans, chickpeas, legumes and whole-grain cereals.
- c. Some good sources of iron are beef, liver, oysters, beans, fortified cereals, pomegranate juice, beets and dark leafy greens.

CHAPTER 7

Nutritional Management of *Angular cheilitis* in Children

Some studies report that children, especially those in slums, are still very much having *angular cheilitis* and malnutrition. This happens because of children sensitivity against certain contact gent like toys, foods, sunlight, allergy against medicines, cosmetics and long term antibiotic treatment (Fajriani, 2017).

Angular cheilitis initial symptoms is itchiness on the corner of the mouth and it looks corner of the mouth and looks appearance inflamed skin and red spots. At first, it is not dangerous but it will feel pain on the corner of the mouth and bleed easily that is caused by the movement of the mouth such as laughing or talking. The inflammation severity is characterized by cracks on corner of the mouth and some bleeding when the patient's mouth opened in *angular cheilitis* associated with nutritional deficiencies can be seen the depletion of tongue papillae (depapillated tongue) due to iron deficiency. The tongue is red and shiny (depapillated glossy red tongue) in patients (Rippon, 1988).

Nutritional status of children in which the main cause of *angular cheilitis* in children is a nutritional deficiency caused by lack of vitamin B complex (riboflavin), iron and folic acid. *Angular cheilitis* caused by vitamin B deficiency should be treated by providing vitamin B complex supplement or multivitamin that contain vitamin B. However, deficiency of one type of vitamin is usually followed by nutritional deficiency, hence in the treatment, multivitamin administration is more effective than

vitamin B complex alone. Reported treatment of disease caused by vitamin B₁₂ deficiency with vitamin therapy can be healed in 3 weeks. The most important thing is to maintain a healthy body so that the immune system is maintained and not susceptible to disease and to eat foods that are nutritionally balanced and needed by the body (Hari, 2010).

Angular cheilitis can occur in chronic condition, where the corner of mouth inflamed because of wound infection. Infection that caused this condition is a type of fungi or bacteria. Affected area usually feels pain and healing period depends on the treatment. The more vulnerable ones are those those with a weak immune system, diabetes mellitus and those that flonDED their saliva on the corner of their lips. Patients who have undergone head and neck radiation also runs the risk of developing *angular cheilitis*, also those who have iron deficiency, vitamin B₁₂ deficiency and folic deficiency (Dowl, 2010).

Iron deficiency anemia seems to predispose to *angular cheilitis*, thus a significantly decreased concentration, of serum iron was demonstrated in a group of patients with *angular cheilitis* and the lesions healed when the diet was supplemented with iron (Zaidan, 2008).

The treatment of *angular cheilitis* depends on its etiology. If the specific etiology remains unfound, these lesions can be difficult to cure and it can last up to several years. It must be remembered that infection is secondary etiology. If the main cause is not treated, the treatment of infection will not produce a permanent result. For example, breathing habit through mouth in child must be stopped, same like the other habits. If it is caused by systemic disease, local treatment will not be successful if not accompanied by systemic treatment. *Angular cheilitis* occurs in children frequently because of lack of nutrition. Bacterial infection and mechanical factor often occur in children with bad habits such as licking

the corner of the lip and sucking finger. These will accumulate the saliva on the corner of the mouth and unwittingly provide perfect environment for infectious agents in causing *angular cheilitis* (Fajriani, 2017). Meningkatkan insightthe community about good nutrition can cause increase of quality intake their nutrition (Ranjan *et al.*, 2016).

For patients not responding to simple therapeutic measures, the next appropriate step is to arrange full hematological screening with measurements of hemoglobin, mean corpuscular volume, folate, vitamin B₂, vitamin B₆, serum iron, ferritin, transferrin, and fasting blood glucose. Nutritional deficiencies, especially of iron and B vitamins, are important in the development of *angular cheilitis* (Warnakulasuriya *et al.*, 1991). Prevalence of *angular cheilitis* and malnutrition status were 75% and 71.90%, respectively. There are sign relationship between nutritional status with *angular cheilitis*. Nutritional status is significantly associated with *angular cheilitis* in school children, at landfill Suwung, Denpasar city (Ari Agung, 2019). *Angular cheilitis* occurs in children frequently because of lack of nutrition. Nutritional status of children in which the main cause of *angular cheilitis* in children is a nutritional deficiency caused by lack of vitamin B complex, iron and folic acid. In causing *angular cheilitis*, each of the etiologic factors, especially nutritional deficiency is correlated with environmental conditions. In students the most influential ones are environmental conditions in both family and school. Referred environmental conditions can be family's socioeconomic level, indigenous influences in the family, habits or eating patterns in children and knowledge about nutrition ((Fajriani, 2017). Overview the nutritional deficiencies implicated in *angular cheilitis*, that can have potentially debilitating effects is shown in Table 1.

Table 1 Nutritional Deficiencies Implicated in *Angular cheilitis* (Kelly *et al.*, 2011)

Etiology	Diagnostic Test	Treatment
Riboflavin (vitamin B ₂)	Elevated RBC glutathione reductase level	5-15 mg daily (Baron, 2011)
Niacin (vitamin B ₃) (Baron, 2011)	2-pyridone and 2-methyl nicotinamide urinary excretion	Nicotinamide (preferred) or nicotinic acid (100-200 mg)
Pyridoxine (vitamin B ₆) (Baron, 2011)	Pyridoxal 5'-phosphate level	50 mg daily or 100-200 mg daily (this dosing if deficiency is drug related)
Biotin (vitamin B ₇) (Forbes <i>et al.</i> , 1997)	Patients may present with <i>angular cheilitis</i> along with other symptoms such as dryeyes and alopecia	150-300 µg per day intramuscularly for 3-5 days (Appel <i>et al.</i> , 1980)
Cyanocobalamin (vitamin B ₁₂) (Baron, 2011)	CBC (megaloblastic anemia), serum cobalamin level, elevated serum methylmalonic acid level	250 µg orally daily; or 30 µg per day intramuscularly for 5-10 days, then maintenance therapy 100-200 µg intramuscularly monthly
Folic Acid (Baron, 2011)	CBC (megaloblastic anemia), serum folate)	Folic acid 5-15 mg orally daily (Adamson, 2012)
Iron (Adamson, 2011)	Serum iron, total iron-binding capacity, serum ferritin	50-65 mg elemental iron orally 3-4 times daily (<300 mg daily)
Zinc (Baron, 2011)	Serum zinc <70 µg/dL	60 mg elemental zinc orally twice daily.

This is consistent with statement that malnutrition is major cause of *angular cheilitis* in the third world countries. Nutrition deficiency may lower the immune system by impairing the cellular, so it

provide of opportunistic infections such as *candida albicans* for the occurrence *angular cheilitis* especially in poor oral hygienes subjects. *Angular cheilitis* occurs in children frequently because of lack of nutrition. Nutritional status of children in which the maincause of *angular cheilitis* in children is a nutritional deficiency caused by lack of protein, vitamin A, B₂, B₆, B₁₂, piridoksin, C, E, folic acid, biotin and mineral Fe, Zn (Budisuari *et al.*, 2010; Rakhmayanti *et al.*, 2016). One type of oral disease that often occurs in the community, especially children when there are nutritional factors is *angular cheilitis* (Fajriani, 2017).

The results of the study of *angular cheilitis* in children with the title "Effect of nutritional intake towards angular disorder of children" from Rahmayanhie *et al.* (2016) concluded that :

1. This is consistent with statement that malnutrition is major cause of *angular cheilitis* in the third world countries. Nutrition deficiency may lower the immune system by impairing the cellular, so it provide of opportunistic infections.
2. There is a significant relationship between the states of nutrition of a child with the occurrence of *angular cheilitis*. Nutritional status of children in which the maincause of *angular cheilitis* in children is a nutritional deficiency caused by lack of protein, vitamin A, B₂, B₆, B₁₂, piridoksin, C, E, folic acid, biotin and mineral Fe, Zn.
3. Most of the *angular cheilitis* that occur can heal itself without antimicrobials, body's defense system should be maintained or increased by administering vitamin supplements or multivitamins.

REFERENCES

- Almatsier S. 2010. *Prinsip Dasar Ilmu Gizi*. Jakarta: Gramedia.p.3-8.
- Anonymous. 2019. Home Remedies for angular cheilitis. Available from <https://www.top10homeremedies.com/> Accessed Mei 5, 2019
- Ari Agung IGA, Wedagama DM, Hartini IGAA, Taha MM, Hervina M. 2017. *Gizi, Kesehatan Gigi dan Mulut Anak Usia Sekolah*. Unmas Press. Unmas Denpasar. p.17-38.
- Ari Agung IGA. 2019. Nutritional status and angular cheilitis in school children at landfill Suwung, Denpasar City. *International Journal of Scientific Publications*; 9 (1).
- Ari Agung IGA. 2016. Gizi, Diet dan Kesehatan Gigi dan Anak. *Interdental* 12(1). pp. 33-35.
- Arisman. 2007. *Gizi dalam Daur Kehidupan*. Jakarta. Penerbit Buku Kedokteran. EGC.
- Atmarita S. 2016. *Analysis of the nutritional and public health situation*. Jakarta : Gramedia Pustaka Utama.
Available from: www.cutis.com. Accessed December 9, 2018
- Ayesh MHMD. 2018. Angular cheilitis induced by iron deficiency anemia. *Cleveland Clinic Journal of Medicine*; 85 (8): 581-582.
- Baron RB. 2011. Nutritional disorders. In: McPhee SJ, Papadakis MA. *Current Medical Diagnosis & Treatment*. 50 th ed. New York, McGraw-Hill
<http://www.accessmedicine.com/content.aspx?aID=16152>. Accessed Juni 19, 2015
- Beck ME. *Ilmu Gizi dan Diet*. 2011. Yogya. Penerbit Andi.
- Budisuari MA, Oktarina, Mikrajas, 2010. Relationships and eating habits brushing teeth with oral health. *B. P. Sistem Kesehatan*, 13 (1) : 17. (In Bahasa Indonesia).
- Cawson RA. 1963. Denture sore mouth and angular cheilitis. *Britis Dental J.* 1963; 115: 441-449.
- Cayer D, Ruffin JM, Perlzweig WA. 1945. The Clinical significance of glossitis in deficiencies of the B-complex.
- Decker RT. Oral manifestation of nutrient deficiencies. *ADA Journal*. 2006:355-61
- Deritana N, Kombong A. Gizi untuk pertumbuhan dan perkembangan. Jayawijaya: *J WATCH*; 2007. p. 5-18.
- Dowl. 2010. Effect of angular cheilitis on children and teenagers. [Internet]. Available at URL:<http://www.EzineArticles/childandac.html>.
- Faiz. 2007. Angular Chelitis – Overview and Symptoms of Angular Chelitis. Available from: URL:<http://www.articlebase.com/skin->

carearticles/angular-chelitis-overview-and-symptoms-of-angular-chelitis-285629.htm

- Fajriani 2017. Management of angular cheilitis in children. *J. of Dentomaxillofacial*, 2(1)
- Field H, Green ME, Wilkinson CW. 1945. Glossitis and cheilosis healed following the use of calcium pantothenate. *Am J Dig Dis*; 38: 111-116.
- Forbes GM, Forbes, A. 1997. A Micronutrient status in patients receiving home parenteral nutrition. *Nutrition*. 1997; 13 : 941-944
- Greenberg MS, Glick M, Ship JA. *Burket' oral medicine : diagnosis & treatment*. 2008. Hamilton: BC Decker Inc.: p 97-98,
- Guyton AC, Hall JE. 2006. *Textbook of Medical Physiology*. 11th ed. Philadelphia : Elsevier Inc. :2006. p. 423-26, 874-7
- Hari S. 2010. Angular cheilitis : Review of etiology and clinical management. Available at : <http://www.trivandrum.co.uk>. Accessed 29 December 2010.
- Pharmacology and therapeutics for dentistry*. St. Louis: Mosby, Elsevier Inc. p.483-95.
- Higgs JM, Wells RS. Chronic mucocutaneous candidiasis : Associated abnormalities of iron metabolism. 1972. *Br. J Dermatol*. 1972; 86 (suppl 8): 88-102
Available at : <https://www.mtatva.com/en/disease/angular>
- Iman D. 2016. Prevalensi angular cheilitis pada anak usia 5-15 tahun di Panti Asuhan Habibie Surabaya. Repository.unair.ac.id/19558/
- Julica MP, 2008. Hubungan dinamis ada antara Gizi dan Karies, Available at : Mawar-Puteri-Julica.blogspot.com. Accessed June 11, 2010.
- Linder MC. 1992. *Biokimia Nutrisi dan Metabolisme, dengan pemakaian secara klinis*. Jakarta. UI Press.
- Morison, MJ. 2003. *Manajemen luka*. Jakarta : EGC.
- Murray JJ, Nunn JH, Steele J, 2008. *The prevention of oral disease* 4thed. New York: Oxford University Press.
- Nesbit SP, Geist. 2017. *Diagnosis and Treatment Planning in Dentistry*. Third Edition.
- Park KK, Brodell RT, Helms SE. 2011. "Angular cheilitis, part 2: nutritional, systemic, and drug-related causes and treatment". *Cutis*. 88 (1).
- Partakusuma FB. 2016. Nutritional status, oral hygiene and angular cheilitis in school children in Cianjur District, West Java. *J. of Dentistry*, 28 (1)
- Pudentiana dan Anggreni, E. 2017. Pengaruh zat gizi bagi kesehatan gigi dan mulut anak usia sekolah (*makalah*). Jakarta. Poltekes

- Kemenkes.
- Purba TE. Latar belakang rongga mulut. 2011. Available from:
URL:<http://repository.usu.ac.id/bitstream/123456789/30455/5/Chapter%20I.pdf>
- Rakhmayanti N, Herawati E, Herawati DMD.. 2016. Effect of nutritional intake towards angular cheilitis of orphanage children. *Padjadjaran Journal of Dentistry*, 28 (3)
- Ranjan R, Reddy T. 2016. Angular cheilitis : Treatment, Diet and Home Remedies in *Tatva Health –PIE*. Available from :
<https://www.mtatwa.com> Accessed : June 9, 2019
- Rippon JW. 1988. *Medical mycology*. 3th ed. Philadelphia : WB Saunders Co.
- Scully C, De Almeida OP, Bagan J, Dioz PD, Taylor AM. *Oral Medicine and Pathology at a Glance*. UK: WilleyBlackwell, 2010; p.37
- Shin-Yu-Lu. 2016. Perception of Iron deficiency from oral muosa alteration that show a high prevalence of Candida infection. *J. Formosan Med. Assoc* 2016: XX-1-9
- Skinner N, Junker JA, Flake D. What Is angular cheilitis and how is it treated?. *The Journal of Family Practice*. 2005;54(5):470- 1.
- Smolin LA, Grosvenor MB. 2005. *Basic nutrition*. New York: Chelsea House, Infobase Publishing. p. 1-3.
- Strumia R. 2005. Dermatologic signs in patients with eating disorders. *Am J Clin Dermatol*. 2005; 6: 165-173.
systemic, and drug-related causes and treatment. *Cutis* 2011.
- Warnakulasuriya KA, Samaranyake LP, Peiris JS. 1991. Angular cheilitis in a group of Sri Lanka adults a clinical and microbiologic study. *J Oral Pathol. Med*. 1991; 20 (4): 172-5.
- WHO. 2019. Good Health for All.
<https://www.who.int/mediacentre/events/goodhealth/en/>
- Wray D, Lowe GD, Dagg JH. 1999. *Textbook of General and Oral Medicine*. New York, NY: Churchill Livingstone.
- Yagiela JA, Dowd FJ, Johnson BS, Mariotti AJ, Neidle EA. 2004. P
- Yuniastuti A. 2008. *Gizi dan Kesehatan*. Yogyakarta. Graha Ilmu.
- Yusran A, Nazaruddin Z, Marlina E. 2013. Efficacy of angular cheilitis therapy in Oral Disease Section. *Makasar Dental J.*, 2 (6)
- Zaidan, T.F., 2008. Angular cheilitis and iron deficiency anemia. *MDJ.*, 5(1)
- Zimmermann MB, Biebinger R, Rohner F, Dib A, Christophe ZC, Hurrell RF, and Chaouki. 2006. Vitamin A supplementation in children with poor vitamin A and iron status increases erythropoietin and hemoglobin concentrations without changing total body iron. *Am. J. Clin. Nutr.* 2006; 84: 580-6.

landfill of Suwung area, help his parents work as "scavengers" or garbage workers. The socio-economic life of the people is still in the middle to the bottom where the environmental and housing conditions are very concerned, there are many piles of garbage strewn, puddles that do not flow, clean water is not available, as well as less hygienic food, is it all becomes the trigger factor of *angular cheilitis* (Partakusuma, 2016). Confirmed also by Atmarita that children living in very unhygienic slums correlate with nutritional deficiencies to the triggering factor of *angular cheilitis* (Atmarita, 2006). This is because children aged 6-12 years including nutritionally vulnerable groups in accordance with the WHO statement that children aged 6-12 years are among the vulnerable groups of nutrition is a group in the community most susceptible to health problems or susceptible to malnutrition (Diana *et al.*, 2015). There are several etiological factors of *angular cheilitis* such as *Candida albicans* fungal infections, nutritional deficiencies, avitaminosis, and bad habits. Candidiasis is a red and creamy mushroom infection that originally looks like a patch formed on a moist surface in the mouth and can cause pain. This condition can cause difficult to swallow and changing the sense of taste. Candidiasis is more common in children with a very low immune system (Murray *et al.*, 2008). This study concluded that the nutritional status of children in landfill of Suwung, Denpasar city has a significant effect on the occurrence of *angular cheilitis*. This is consistent with statement that malnutrition is major cause of *angular cheilitis* in the third world countries. Nutrition deficiency may lower the immune system by impairing the cellular, so it provide of opportunistic infections such as *candida albicans* for the occurrence *angular cheilitis* especially in poor oral hygiene subjects. *Angular cheilitis* occurs in children frequently because of lack of nutrition. Nutritional status of children in which the main cause of *angular cheilitis* in children is a nutritional deficiency caused by lack of protein, vitamin A, B₂, B₆, B₁₂, piridoksin, C, E, folic acid, biotin and mineral Fe, Zn (Budisuari *et al.*, 2010; Rakhmayanti *et al.*, 2016). One type of oral disease that often occurs in the community, especially children when there are nutritional factors is *angular cheilitis* (Fajriani, 2017).

In this study, it was found that in subjects with normal nutritional status experienced *angular cheilitis* were 12,5%. Similarly found in this study prevalence of respondents (9.4%) who had below malnutrition status did not experience *angular cheilitis*. This can happen because of nutritional status measurements by using CDC BMI-for-age percentile growth chart. This is in accordance with the opinion of Fajriani and Greenberg that although the child's nutritional status is normal, the child may have vitamin B₂, B₁₂, B₆, piridoksin, folic acid, Fe, or biotin deficiency, is it all becomes the trigger factor of *angular cheilitis* (Fajriani, 2017; Greenberg, *et al.*, 2008). There is debate about the causes of *angular cheilitis* and many factors suspected about the pathogenitas, including malnutrition and infection. Any etiologic factor causing *angular cheilitis* especially nutritional deficiency correlates with slum environmental conditions. Bacterial infection and mechanical factor often occur in children with bad habits such as licking the corner of the lip and sucking finger. These will accumulate the saliva on the corner of the mouth and unwittingly provide perfect environment for infections agents in causing between *angular cheilitis* and large intake of carbohydrates has been shown, and it was assumed that a high salivary concentration of 384 glucose predispose to infection, in the angles of the mouth (Atmarita, 2006).

V. CONCLUSION

This study was found 75% respondents there are *angular cheilitis* and 71,9% respondents there are below malnutrition. Nutritional status is significantly associated with *angular cheilitis* incident in school children, in landfill of Suwung, Denpasar city.

REFERENCES

- Atmarita, S. *Analysis of the nutritional and public health situation Jakarta* : Gramedia Pustaka Utama. 2016.
- Budisuari, M.A., Oktarina, Mikrajas. Relationships and eating habits brushing teeth with oral health. B. P. *Sistem Kesehatan*, 13 (1): 17. 2010.
- Diana, S., E.S. Rinna, D. Indeswati. The role of sorbitol in maintaining salivary pH stability in the caries prevention process. *Dent. J.* 38 (1), 2005
- Fajriani, .Manajement of *angular cheilitis* in children. *J. of Dentomaxillofacial*, 2(1): 2017.